New-Generation Implant Arthroplasties of the Finger Joints

Peter M. Murray, MD

Abstract

Prosthetic replacement in the hand must address such unique challenges as preservation of the collateral ligaments, tendon balancing, and stability. Some recently developed implant arthroplasties of the metacarpophalangeal and proximal interphalangeal joints have anatomically designed articular components; others have noncemented, press-fit, carefully contoured intramedullary stems. The rationale behind developing the unlinked or semiconstrained prosthesis with anatomic geometry is that it would create balanced forces across the joint. Low-profile, anatomically designed implants limit the amount of bone removed and preserve the integrity of the collateral ligaments. A metacarpophalangeal joint implant with an elliptical metacarpal head and a nonfixed center of rotation can enhance stability in flexion through greater articular contact. A proximal interphalangeal joint implant that preserves the collateral ligaments also can achieve improved stability. Component loosening is not an early complication with these recent designs, and arc of motion is satisfactory.

J Am Acad Orthop Surg 2003;11:295-301

The primary goals of finger joint arthroplasty are to alleviate pain, restore stability, and preserve or enhance motion. Early digital implants, such as the Vitallium cap for arthroplasty of the metacarpophalangeal (MCP) and proximal interphalangeal (PIP) joints,[1] were developed with concepts similar to those used in successful implant arthroplasty of the lower extremity. However, finger total joint arthroplasty has been slow to develop, primarily because of early design failures. The Swanson hinged Silastic spacer is the most commonly used implant for PIP and MCP joint reconstruction, particularly for patients with rheumatoid arthritis, in whom 90% 10-year survivorship has been reported.[2,3]

In 1959, Brannon and Klein[1] published the results of the first series of a digital total joint replacement. They reported encouraging results with a hinged prosthesis initially indicated for the severely traumatized PIP joint.[1] Two years later, Flatt[4] reported on the use of a more rotationally stable modification of the Brannon prosthesis for the rheumatoid MCP joint.[5] These first-generation hinged designs failed because of a nonanatomic center of rotation, a high coefficient of friction at the hinge mechanism, metallic implant debris, and, ultimately, breakage.[6,7] The second generation of hinged prostheses had a ball-and-socket design, with the intent of allowing adduction and abduction in addition to flexion and extension.[6] These metal-on-plastic MCP joint designs included the Griffiths-Nicolle, the Schetrumpf, the Steffee, the Walker, and the Schultz. These implants were fraught with complications, including proximal phalangeal component failure, hypertrophic bone formation, poor motion, and instability.[7,8]

In 1979, Linscheid and Dobyns[9] developed a prototype of a PIP joint prosthesis, which they called surface replacement arthroplasty, that was intended to preserve the collateral ligaments and thus unload the component stems. Other MCP and PIP joint designs were subsequently developed, including the Keesler, the Hagert, and the Sibly-Unsworth.[5,6] Recent design modifications and longer follow-up of these early prototypes has generated continued interest in anatomic, minimally constrained PIP and MCP joint designs. Other new European designs, such as the Saffar (Dimso SA, Mernande, France), the Digitale (Procerati, Paris, France), the WEKO Fingergrundgelenk (Implant-Service, Hamburg, Germany), and the DJOA3 (Landos, Malvern, PA), were developed to improve intramedullary fixation rather than anatomic configuration of the articular surfaces.[7,10,11]

Dr. Murray is Associate Professor, Department of Orthopedic Surgery, Division of Hand and Microsurgery, The Mayo Clinic, Jacksonville, FL.

Neither Dr. Murray nor the department with which he is affiliated has received anything of value from or owns stock in a commercial company or institution related directly or indirectly to the subject of this article.

Reprint requests: Dr. Murray, 4500 San Pablo Road, Jacksonville, FL 32224.

PIP Joint Implant Arthroplasty

The principal shortcoming of previous metallic, metalloplastic, and single-component polymeric plastic-hinged designs was the amount of bone resection required for implantation. The extent of resection frequently violated the origin and insertion of the collateral ligaments. The two primary stabilizing factors of the PIP joint are the bicondylar geometry of the articulation and the collateral ligaments.[12,13] The extensor mechanism also may be considered a stabilizer.[12,13] In the absence of the two primary stabilizers, the stems of the monoaxial-hinged design of the first-generation PIP joint arthroplasty bore high loads, which frequently resulted in loosening, cortical penetration, and subsidence.[1,4-6,12,14] Subsequent hinged or fully constrained linked designs were unable to ameliorate these shortcomings.

The natural flexibility of the Swanson Silastic spacer offers greater longevity compared with previous metallic-hinged designs. The hinge resists prolonged cyclic loading but is prone to fracture at the stem-hinge junction. However, these implants continue to function after breakage in rheumatoid patients. The Swanson Finger Joint Implant (Wright Medical Technology, Arlington, TN) is the most commonly used PIP joint arthroplasty device, but it is generally not recommended for the index or long fingers of active individuals.[9,15] The generous resection of the proximal phalangeal head required by the Swanson Silastic spacer sacrifices the radial and ulnar collateral ligaments of the PIP joint. Resection of the collateral ligaments leaves the Silastic implants of the index and long digits vulnerable to pinch stresses. External pinch forces of 70 N are considered normal, with resultant forces on the PIP joint postulated to be as high as six times the externally applied force.[6] A successful arthroplasty must be able to sustain these transmitted forces.

The rationale behind new-generation arthroplasty of the PIP joint is that a minimally constrained, unlinked prosthesis with an anatomic center of rotation would balance forces acting across the joint. In theory, preservation of bone stock and collateral ligaments lends enhanced stability to the arthroplasty beyond that which can be accomplished with a Silastic spacer alone. Also, greater durability can be expected compared with earlier hinged designs. The anatomic configuration, in combination with retention of the collateral ligaments and PIP joint capsule, should reduce axial torque from the bone-prosthesis interface.[12] Ash and Unsworth[16] demonstrated that an anatomically designed PIP joint surface replacement arthroplasty could withstand pinch force >65 N. They also showed that an ultra-high–molecular-weight (UHMW) polyethylene material for both weight-bearing surfaces could produce wear rates similar to those of metal-on-polymer.[16]

The SR PIP Finger Prosthesis (Avanta, San Diego, CA) has a stemmed, bicondylar proximal phalangeal component milled from cobalt-chromium (CoCr). The middle phalangeal component of this PIP joint implant is machined from UHMW polyethylene, which is supported by a thin titanium backing and stem. The articular surfaces of the components are congruent. Both components have stems designed to fit the internal contours of the medullary canal. The low-profile design of the PIP joint surface replacement arthroplasty reduces the amount of bone removed and preserves the integrity of the lateral collateral ligaments (Fig. 1). Four different sizes have been made of each component. The PIP joint surface replacement implant is approved for revision arthro-

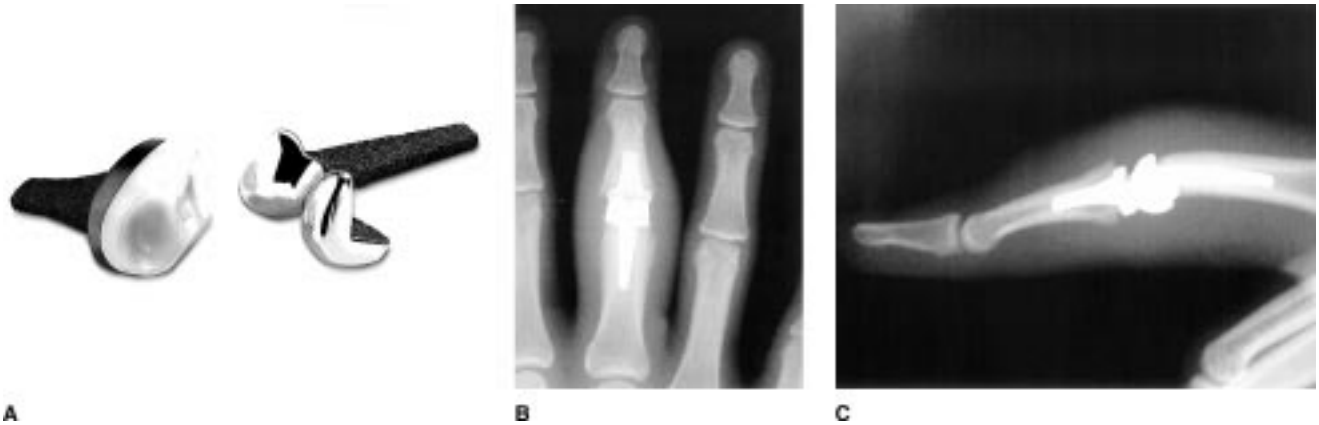

Figure 1 **A,** Titanium-backed UHMW polyethylene middle phalangeal (left) and bicondylar CoCr proximal phalangeal (right) components of the SR PIP Finger Prosthesis. (Reproduced with permission from Avanta, San Diego, CA.) Anteroposterior **(B)** and lateral **(C)** postoperative radiographs of PIP joint surface replacement arthroplasty for posttraumatic degenerative arthritis of the PIP joint. Notice the titanium-backed, second-generation middle phalangeal component.

plasty of the PIP joint, for arthroplasty in the painful osteoarthritic PIP joint, and for the posttraumatic arthritic PIP joint. This prosthesis seems less desirable in settings of pronounced bone loss or when the collateral ligaments are missing or incompetent.

Other recent PIP joint arthroplasty designs include the Saffar, the Digitos (Osteo AG, Selzach, Switzerland), the DJOA3, and the WEKO Fingergrundgelenk prostheses. Although labeled semiconstrained by their manufacturers, the DJOA3 and Saffar prostheses have a prominent stabilizing midline crest between the proximal and distal components. Notably, the DJOA3 (Fig. 2) does not require preservation of the collateral ligaments and is composed of a stainless steel proximal component and a polyethylene distal component. The Saffar is a similarly designed, noncemented semiconstrained titanium-polyethylene prosthesis.[7] The Digitos prosthesis (Fig. 3) is a modular, fully constrained second-generation PIP joint prosthesis specifically designed for unstable joints without collateral ligaments. Similarly, the WEKO Fingergrundgelenk prosthesis is a constrained design that fits into intramedullary bone sleeves (Fig. 4).

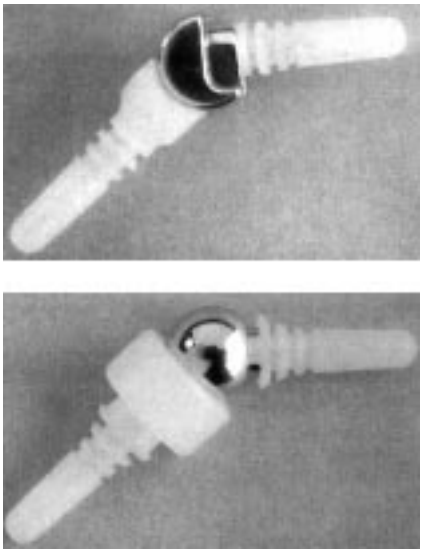

Figure 2 The DJOA3 PIP (top) and MCP (bottom) joint prostheses. (Reproduced with permission from Linscheid RL: Implant arthroplasty of the hand: Retrospective and prospective considerations. *J Hand Surg [Am]* 2000;25:796-816.)



Figure 3 The Digitos PIP joint prosthesis. (Reprinted with permission from Linscheid RL: Implant arthroplasty of the hand: Retrospective and prospective considerations. *J Hand Surg [Am]* 2000;25:796-816.)

Technique

Several surgical approaches, including the dorsal, lateral, and palmar, have been used during the evolution of PIP joint arthroplasty.[12] Unique difficulties can occur with each approach because important structures must be sacrificed or incised during the exposure. The central slip is vulnerable with the dorsal approach. The collateral ligaments are at risk with the traditional lateral approach. The volar plate and the flexor tendon sheath are at risk with the palmar approach. Linscheid et al[12] reported an increased incidence of late swan-neck deformities in patients undergoing PIP joint surface replacement arthroplasty when the palmar approach was used. In contrast, Lin et al[17] reported no instances of swan-neck deformity or flexor tendon bowstring in 69 silicone arthroplasties using the palmar approach.[17] The approach preferred by Linscheid et al[12] for the PIP joint surface replacement is the modified dorsal approach described by Chamay,[18] which offers a generous exposure of the PIP joint through a distally based triangular flap of the extensor mechanism (Fig. 5). Before entering the joint, thin remnants of the dorsal PIP joint capsule are incised. The radial and ulnar collateral ligaments are protected using small Homan retractors. Judicious placement of these retractors brings the base of the middle phalanx into full view.

For any type of PIP joint arthroplasty performed through a dorsal approach, an osteotomy of the base of the middle phalanx is done through the subchondral bone, perpendicular to the long axis of the phalanx. The collateral ligament insertion should be protected during the osteotomy, although a small portion of the insertion may need to be undermined.[19] Minamikawa et al[13] have shown in a cadaveric model that the PIP joint remains stable even after half of the collateral ligament substance is removed. After preparation of the middle phalanx base, an osteotomy of the proximal phalangeal head is done using a microsagittal saw. A small bur is used to shape the resected proximal phalangeal head to accept the desired prosthetic device. The proximal and middle phalanges are appropriately broached, and trial components are inserted. The permanent components are implanted once sizing for best fit is completed. Polymethylmethacrylate in a semifluid state is used for the Avanta SR PIP Finger Prosthesis, but many of the other new-generation de-

Figure 4 The WEKO Fingergrundgelenk prosthesis. (Reprinted with permission from Linscheid RL: Implant arthroplasty of the hand: Retrospective and prospective considerations. *J Hand Surg [Am]* 2000;25:796-816.)

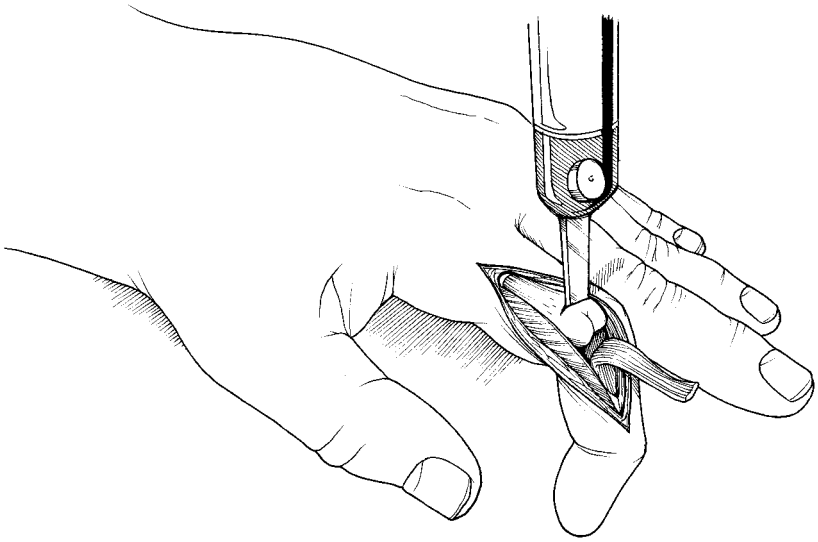

Figure 5 Chamay approach to the PIP joint, with distally based flap of extensor mechanism raised to expose the joint. (Adapted with permission from Avanta, San Diego, CA.)

signs are press-fit. Rehabilitation is initiated by postoperative day 5 in most cases. A dynamic extension splint is applied for 4 weeks, permitting active flexion and dynamic extension.

Results

The Swanson silicone implant is the most studied prosthesis for reconstruction of the rheumatoid PIP joint. Ashworth et al[2] reported on PIP joint silicone implants at an average follow-up of 5.8 years. Pain was not present in 67% of joints, and prosthesis survivorship was 81% at 9 years. The mean postoperative arc of motion was 29°, compared with a preoperative mean of 38°. Complications in this series were negligible. Lin et al[17] reported on 69 silicone PIP joint spacers (48 with primary or posttraumatic osteoarthritis) at a mean follow-up of 3.4 years. Mean postoperative range of motion was 46° compared with 44° preoperatively. There were 12 joints with complications.

In 1997, Linscheid et al[12] published initial results for the SR PIP Finger Prosthesis. Sixty-six joint surface replacement arthroplasties were inserted, mostly in patients with osteoarthritis. There were 32 good results, 19 fair, and 15 poor at a mean follow-up of 4.5 years. This series combined results from several generations of the evolving surface replacement design. Arthroplasties performed through a dorsal approach yielded better results than those done through a lateral or palmar approach. Complications, including instability, ulnar deviation, swan-neck deformity, flexion contracture, tenodesis, and joint subluxation, occurred in 19 of the 66 arthroplasties. No components showed evidence of loosening. Range of motion at follow-up averaged from –14° extension to 61° flexion. The postoperative arc of motion was 41°, an improvement of 12° over preoperative motion.

To date, published results are not available for the Saffar and Digitos prosthetic devices. Condamine et al[10] reported the results of the DJOA3 implant (Fig. 2), which they consider a third-generation PIP joint prosthetic device. These results suggest satisfactory function in 110 implanted prostheses with only 3% loosening. However, 80% of the patients in this series had been followed for <1 year.

MCP Joint Implant Arthroplasty

Stability, recurring deformity, loosening, and tendon balancing are the primary challenges facing the design of a replacement for the MCP joint.[5,20] A common problem in MCP total joint designs has been the appropriate location of the center of rotation for the metacarpal head component.[5] Incorrect placement of the center of rotation hinders joint flexion and extension. If the center of rotation of an MCP joint prosthesis is placed too dorsal, digital extension becomes difficult but flexion is enhanced. Placement of the center of rotation in a palmar direction may limit digital flexion but may enhance digital extension.[5] In the native joint, the center of rotation of the MCP joint in relation to the metacarpal head is not fixed because the sagittal contour of the head is elliptical. The movements of the normal MCP joint produce both abduction and adduction, along with some rotation.[21] Finally, three-dimensional models of the hand have shown that internally transmitted compression joint forces can range to as high as six times the externally applied pinch force.[21] Theoretically, the design of a prosthetic joint would be superior if the design closely approached the normal anatomic configuration. Such a design would allow the sliding and rotational movements typically observed. However, shortcomings of an anatomically configured design are the potential for instability or subluxation, particularly when ligamentous incompetence is present.

The MCP PyroCarbon Total Joint Prosthesis (Ascension Orthopedics, Austin, TX) is an unlinked MCP joint implant. The pyrolytic carbon coating is applied to a high-strength graphic substrate to create an implant that is highly compatible with living tissue.[22] The components have offset intramedullary stems, which support hemispheric articulating surfaces

(Fig. 6). The offset intramedullary stems presumably help neutralize ulnarly directed forces. These articulating surfaces resemble, but do not anatomically replicate, the metacarpal head and the articular base of the proximal phalanx. The implant is very effective in implant-bone load transfer because of an elastic modulus similar to that of cortical bone.[22] The pyrolytic carbon material has been shown to be very stable in a primate model, producing no wear, wear debris, or inflammatory reaction. The low profile of the MCP PyroCarbon Total Joint Prosthesis is designed to preserve the collateral ligaments.

Based on the same design concepts used for the development of the SR PIP Finger Prosthesis, the SR MCP Finger Prosthesis (Avanta) is a minimally constrained, unlinked design that attempts to reestablish the anatomic geometry of the metacarpal head. The metacarpal component is made of CoCr; the proximal phalanx component is manufactured of UHMW polyethylene (Fig. 7). The metacarpal head component is elliptical in an attempt to approximate the changing center of rotation in the natural MCP joint. Furthermore, the metacarpal head prosthesis has volar flanges, thereby enhancing surface contact in flexion. This enhanced contact in flexion increases radioulnar stability.[19] This prosthesis has been designed to help compensate for the soft-tissue imbalance often encountered at the MCP joint in the rheumatoid patient. The dorsal lip of the proximal phalangeal component has been extended to prevent palmar subluxation of the joint. Additionally, the metacarpal component has a central raised portion designed to inhibit ulnar drift. The metacarpal head also is offset radially on its stem to help decrease ulnarly directed moments.[7] Perhaps more important than any other stabilizing design feature, the low-profile nature of the prosthesis retains the origin and insertion of the collateral ligaments. Therefore, the MCP joint surface replacement arthroplasty ultimately may be appropriate for both osteoarthritis and rheumatoid arthritis. However, certain conditions encountered in patients with rheumatoid arthritis, such as severe bone erosion and collateral ligament incompetence, may create limitations for the use of this device.

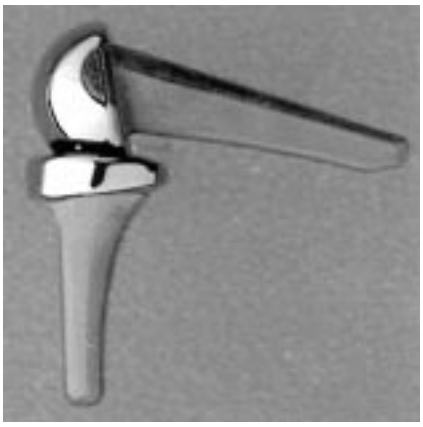

Figure 6 The MCP PyroCarbon Total Joint Prosthesis. (Reproduced with permission from Ascension Orthopedics, Austin, TX.)

Figure 7 UHMW polyethylene proximal phalangeal (left) and CoCr metacarpal (right) components of the SR MCP Finger Prosthesis. (Reproduced with permission from Avanta, San Diego, CA.)

Several other MCP joint prostheses recently have been developed. The Saffar implant is a noncemented, semiconstrained titanium-polyethylene MCP joint prosthesis with a central articulating crest for stability. The Digitale MCP prosthesis has titanium-coated, anatomically shaped, stainless steel press-fit stems designed to stimulate bony ingrowth. The Mathys MCP RM Finger System (Mathys, Bettlach, Switzerland) uses a polyacetal-resin proximal component and a polyester distal component. This prosthesis has the unique feature of a screw-expanded intramedullary fixation for enhanced intramedullary fit[21] (Fig. 8). The DJOA3 MCP joint implant (Fig. 2) studied by Condamine et al[10] has a spherical stainless steel head and a cylindrical polyethylene proximal phalangeal component.

Technique

For a single-digit arthroplasty, the extensor mechanism of the MCP joint is exposed under tourniquet control through a longitudinal incision. If multiple joints are to be replaced, a transverse incision is preferable. The extensor mechanism is dissected in such a way that relocation can be accomplished at the time of wound closure. In most situations, it is possible to preserve and imbricate the sagittal bands separately from the dorsal MCP joint capsule. In patients with rheumatoid arthritis, it is necessary to do this to correct digital ulnar drift. Some surgeons prefer to incise the extensor mechanism along its radial border to imbricate the extensor tendon on the radial sagittal band. This can be combined with an incision along the ulnar border of the extensor tendon to facilitate radial mobilization of the extensor tendon, especially in the contracted state. Alternatively, the extensor mechanism can be incised along its ulnar border, and the extensor tendon can be centralized by creating a

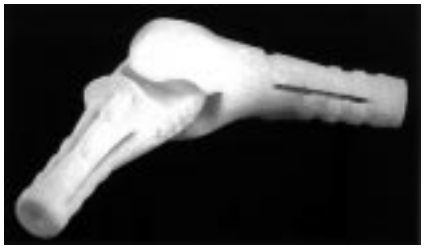

Figure 8 The MCP RM Finger System. (Reprinted with permission from Linscheid RL: Implant arthroplasty of the hand: Retrospective and prospective considerations. *J Hand Surg [Am]* 2000;25:796-816.)

sling made either of the radial sagittal band or from the extensor tendon itself.

The capsule is then longitudinally incised to fully expose the MCP joint. In most designs, a metacarpal sizing template is used to determine the amount of bone to be resected so that the collateral ligaments are spared. Next, the base of the proximal phalanx is prepared by a thin osteotomy perpendicular to the longitudinal axis of the phalanx. With this proximal phalanx osteotomy, only the articular surface and subchondral bone are removed (Fig. 9). Awls are used to enter the intramedullary canals of the metacarpal and the proximal phalanx; the respective intramedullary canals are sequentially broached until the appropriate fit is obtained. Trial components are inserted and reduced, and the joint is tested for stability and range of motion. Depending on the prosthesis chosen, the metacarpal and phalangeal components are inserted using polymethylmethacrylate or are press-fit. For patients with ulnar drift, the extensor mechanism is then centralized using an imbrication technique. Postoperative rehabilitation involves a dynamic extension outrigger splint permitting active flexion and passive extension for approximately 4 weeks. This is often followed by a nighttime resting hand splint for an additional 6 weeks.

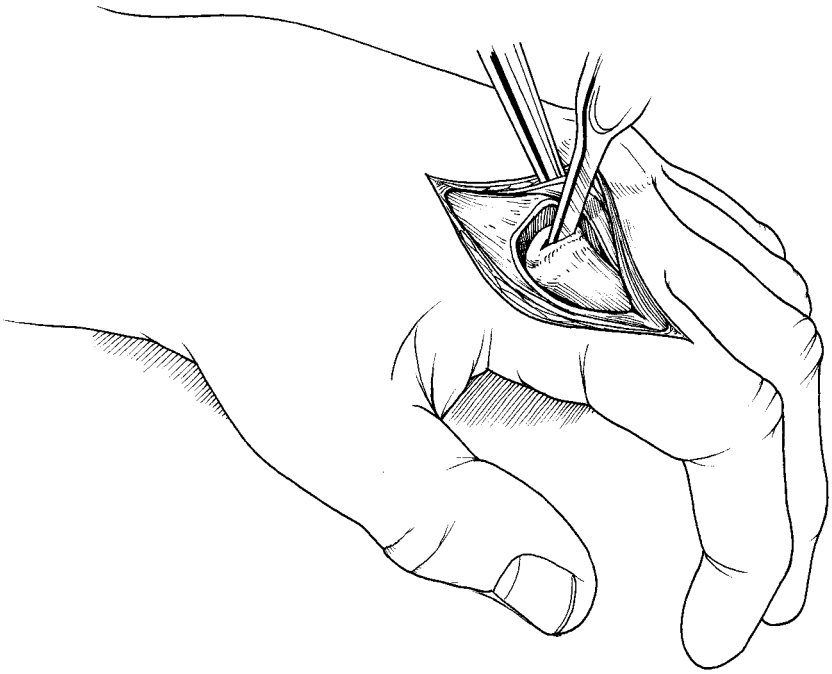

Figure 9 Thin, transverse subchondral osteotomy of the proximal phalanx in preparation for MCP joint arthroplasty. (Adapted with permission from Avanta, San Diego, CA.)

Results

Clinical experience with the Swanson Silastic MCP joint spacer is greater than with any new-generation MCP joint arthroplasty device. The results of using a new MCP joint prosthesis thus must be compared with the gold standard, the Silastic MCP joint spacer. Hansraj et al[3] reported the results of 170 Swanson Silastic MCP joint spacers at a mean follow-up of 5.2 years. No pain was reported in 54% of these joints. Mean postoperative arc of motion was 27°, compared with 38° preoperatively. Prosthesis survivorship at 10 years was 90%. Blair et al[23] reported the results of 115 Swanson Silastic implants at a mean follow-up of 54 months. Mean MCP joint motion was 43° (13° extension to 56° flexion), and ulnar drift recurred in 43% of fingers (49 / 115). Furthermore, arc of motion is known to be in a more extended position after Silastic MCP joint spacer placement.[23,24]

The MCP joint surface replacement arthroplasty has been available in Europe for 8 years and is currently under clinical trial in the United States. No series has been published reporting results. Although theoretically there are advantages to the use of the MCP joint surface replacement arthroplasty, currently it cannot be considered a replacement for the Swanson Silastic MCP joint spacer.

Primate studies have shown no evidence of debris or inflammatory reaction after implantation of the pyrolytic carbon MCP joint arthroplasty.[25] Good bone incorporation of the prosthesis also was observed. A subsequent series of 151 MCP PyroCarbon Total Joint Prostheses (Ascension Orthopedics) implanted over an 8-year period was followed up at a mean of 11.7 years.[22] Most patients had rheumatoid arthritis. The arc of MCP joint motion improved a mean of 13°. The 10-year survivorship was 81.4%. At long-term follow-up, those joints with ulnar drift had developed recurrent ulnar drift to the degree identified preoperatively. Complications led to 18 implant revisions (12%).[22]

Summary

The primary challenges to anatomically shaped arthroplasties in the fingers are joint stability, rebalancing of tendons, and prevention of prosthetic loosening. Surface replacement designs limit bone resection and preserve the integrity of collateral ligaments. Preservation of bone stock and collateral ligaments maintains stability while reducing axial torque at the

bone-cement interface. This is in contrast with earlier implants, which were highly constrained, did not offer sufficient degrees of freedom, and failed to duplicate the normal center of motion. When marked bone loss is present or collateral ligaments have been rendered incompetent, more constrained designs may be more appropriate. The best results with the longest follow-up of any hand total joint arthroplasty have been reported with use of the pyrolytic carbon MCP implant, which has successfully completed formal FDA review and has been released for general use.

Initial reports of the PIP and MCP joint surface replacement implants are encouraging, particularly because the component loosening typical of earlier designs has not been a problem to date. However, recurrent joint deformity and limited motion remain challenges for the surface replacement prostheses as well as for other new-generation digital joint implants. The Swanson Silastic spacer has been a viable alternative for the patient with rheumatoid arthritis and has achieved consistent patient satisfaction. Nevertheless, the concept of surface replacement arthroplasty for finger joints may provide the opportunity both to extend indications and to provide more durable functional results.

References

1. Brannon EW, Klein G: Experiences with a finger-joint prosthesis. *J Bone Joint Surg Am* 1959;41:87-102.
2. Ashworth CR, Hansraj KK, Todd AO, et al: Swanson proximal interphalangeal joint arthroplasty in patients with rheumatoid arthritis. *Clin Orthop* 1997;342: 34-37.
3. Hansraj KK, Ashworth CR, Ebramzadeh E, et al: Swanson metacarpophalangeal joint arthroplasty in patients with rheumatoid arthritis. *Clin Orthop* 1997;342:11-15.
4. Flatt AE: Restoration of rheumatoid finger-joint function: Interim report on trial of prosthetic replacement. *J Bone Joint Surg Am* 1961;43:753-774.
5. Beevers DJ, Seedhom BB: Metacarpophalangeal joint prostheses: A review of the clinical results of past and current designs. *J Hand Surg [Br]* 1995; 20:125-136.
6. Beevers DJ, Seedhom BB: Metacarpophalangeal joint prostheses: A review of past and current designs. *Proc Inst Mech Eng [H]* 1993;207:195-206.
7. Linscheid RL: Implant arthroplasty of the hand: Retrospective and prospective considerations. *J Hand Surg [Am]* 2000;25:796-816.
8. Adams BD, Blair WF, Shurr DG: Schultz metacarpophalangeal arthroplasty: A long-term follow-up study. *J Hand Surg [Am]* 1990;15:641-645.
9. Linscheid RL, Dobyns JH: Total joint arthroplasty: The hand. *Mayo Clin Proc* 1979;54:516-526.
10. Condamine J, Marcucci L, Bisson P, Lebrieton L: DJOA arthroplasty: Ten years of experience, in Schuind F, Cooney WP, An K-N, Garcia-Elias M (eds): *Advances in Biomechanics of the Hand and Wrist*. New York, NY: Plenum Press, 1996, pp 76-83.
11. Saffar P: La fixation prothetique: Generalities, in Table Ronde sur les prosthesies interphalangiennes proximales: Congrès de la Société Française de Chirurgie de la Main. *La Main* 1997;2:107-109.
12. Linscheid RL, Murray PM, Vidal MA, Beckenbaugh RD: Development of a surface replacement arthroplasty for proximal interphalangeal joints. *J Hand Surg [Am]* 1997;22:286-298.
13. Minamikawa Y, Horii E, Amadio PC, Cooney WP, Linscheid RL, An KN: Stability and constraint of the proximal interphalangeal joint. *J Hand Surg [Am]* 1993;18:198-204.
14. Flatt AE, Ellison MR: Restoration of rheumatoid finger joint function: III. A follow-up note after fourteen years of experience with a metallic-hinge prosthesis. *J Bone Joint Surg Am* 1972;54:1317-1322.
15. Amadio PC: Arthroplasty of the proximal interphalangeal joint, in Morrey BF (ed): *Joint Replacement Arthroplasty*. New York, NY: Churchill-Livingstone, 1991, pp 147-157.
16. Ash HE, Unsworth A: Design of a surface replacement prosthesis for the proximal interphalangeal joint. *Proc Inst Mech Eng [H]* 2000;214:151-163.
17. Lin HH, Wyrick JD, Stern PJ: Proximal interphalangeal joint silicone replacement arthroplasty: Clinical results using an anterior approach. *J Hand Surg [Am]* 1995;20:123-132.
18. Chamay A: A distally based dorsal and triangular tendinous flap for direct access to the proximal interphalangeal joint. *Ann Chir Main* 1988;7:179-183.
19. Berger RA, Beckenbaugh RD, Linscheid RL: Arthroplasty in the hand and wrist, in Green DP, Hotchkiss RN, Pederson WC (eds): *Green's Operative Hand Surgery*, ed 4. New York, NY: Churchill Livingstone, 1999, vol 1, pp 147-191.
20. Tamai K, Ryu J, An KN, Linscheid RL, Cooney WP, Chao EY: Three-dimensional geometric analysis of the metacarpophalangeal joint. *J Hand Surg [Am]* 1988;13:521-529.
21. Beevers DJ, Seedhom BB: Design of a non-constrained, non-cemented, modular, metacarpophalangeal prosthesis. *Proc Inst Mech Eng [H]* 1995;209:185-195.
22. Cook SD, Beckenbaugh RD, Redondo J, Popich LS, Klawitter JJ, Linscheid RL: Long-term follow-up of pyrolytic carbon metacarpophalangeal implants. *J Bone Joint Surg Am* 1999;81:635-648.
23. Blair WF, Shurr DG, Buckwalter JA: Metacarpophalangeal joint implant arthroplasty with a Silastic spacer. *J Bone Joint Surg Am* 1984;66:365-370.
24. Madden JW, De Vore G, Arem AJ: A rational postoperative management program for metacarpophalangeal joint implant arthroplasty. *J Hand Surg [Am]* 1977;2:358-366.
25. Cook S, Beckenbaugh R, Weinstein A, Klawitter J: Pyrolite carbon implants in the metacarpophalangeal joint of baboons. *Orthopedics* 1983;6:952-961.