

Endofibrosis of the Iliac Arteries : an Underestimated Problem

P. Feugier, J.-M. Chevalier

Vascular Surgery Department, Edouard Herriot Hospital, Lyon, France.

Key words. Endofibrosis ; external iliac artery ; vascular disease ; athlete.

Abstract. Arterial endofibrosis is a recently discovered artery disease that is specific to endurance athletes. Cycling is the sport that has shown the greatest number of cases. The endofibrosis is located most frequently in the external iliac artery, but other locations must also be sought. Thigh pain during supramaximal exercise and patient questioning provide strong indications. The diagnosis is confirmed when there is concordance of exercise-induced symptoms, a positive exercise test result and discrete arteriographic characteristics. Treatment is based on folate supplements and standardised surgery carried out by an experienced surgical team.

Review paper

Introduction

Arterial endofibrosis is a non-atheromatous vascular pathology specific to athletes. It is defined histologically : an intimal subendothelial paucicellular fibrosis leading to wall thickening and the reduction of the artery lumen caliber. Although cyclists are the most often affected, athletes competing in other endurance sports are also vulnerable. This fibrosis is located predominantly on the external iliac artery (EIA). However, it can also reach the common iliac artery and involve the femoral artery or the profunda femoris artery. Although it is only in rare cases that it leads to invalidating symptoms during mild exercise, it limits the athlete in long-duration exercise and performance. Recently discovered, its pathogenesis is increasingly well understood (1, 2). It requires specific exploratory studies and standardised management.

From 1991 to 2003, our experience has included 350 lesions of endofibrosis treated surgically in 334 patients.

Discussion

Histology

Microscopic and macroscopic aspect

Fibrosis is most often excentric, producing a whiteish, elastic plaque that separates very easily from the artery wall (3). It is predominantly located on the convex side of the artery's kinks and produces stenoses averaging 50%.

Histological observation confirms a subendothelial plaque made up of cells analogous to myofibroblasts surrounded by collagen and a substance that is fundamental-

ly rich in proteoglycans and mucopolysaccharides (4). The elastica interna is most often doubled or ruptured. The media is intact while the adventitia contains more numerous smooth muscle cells facing the plaque.

Histological classification

Two histological forms have been differentiated : the habitual forms and the compound forms (Table 1) (5). The excentric forms are the most frequent and present typical histological characteristics. The plaque can be circumferential and in this case always has an asymmetrical distribution. There is a multi-layered type of superimposed eccentric or circumferential lesion of different ages, with the different layers separated by newly formed elastica.

An endofibrosis lesion can be complicated by a fibrous plaque thrombosis, a dissection of the tunica media on the side of the lesion, or an atheromatous infiltration (6). This latter histological form is most often seen in patients over 40 years of age.

Epidemiology

Current data (Table 2)

It is very difficult to evaluate the incidence of this disease in the population or in people who regularly take part in endurance sports. It appears predominantly in professional or amateur bicycle racers. Patients often began cycle racing in childhood (mean age, 12-14 years). The mean age of patients undergoing surgery is 27 years (range, 18-61 years). Although the average mileage covered since the beginning of training is a factor that should be taken into account, we believe that the intensity of this training is an even more important element in the genesis of the lesion (14,500 km / year on average).

Table 1
Histological classification

Classes	Types	Frequency	Histological characteristics
habitual forms (85%)	– eccentric – several layers – circumferential	49% 19% 17%	subendothelial fibrous hyperplasia concentric lesions of different ages affected in entire circumference
compound forms (15%)	– with atheroma – with thrombosis – with dissection	9% 4% 2%	presence of spumous cells and fibrous blood debris – –

Table 2
Epidemiological data from our experience

Sports	Patients (%)	Sex ratio	Strandness test			Treatment		
			Positive	Suspect	Negative	PTA	Endofibrosectomy	Bypass
Cycling	298 (89%)	5 F / 293 M						
– Professionals	49 (15%)		280 lesions	32 lesions	38 lesions	3	237	110
– Amateurs	214 (75%)		80%	9%	11%	1%	68%	31%
– Recreational cyclists	35 (10%)							
Other sports	36 (10%)	16 F / 20 M						

The majority of patients that were operated on were male (93%). This incidence is most certainly biased by the high percentage of men who participate in cycling and the differences in work load during training. Indeed, the sex ratio is close to 50% for other sports.

Arterial endofibrosis has been observed in other endurance sports : running, rowing, triathlon, race walking and also rugby (7-9).

Location

In 90% of cases, arterial endofibrosis is located in the EIA. However, 47 patients (14%) presented an unusual location, isolated or associated with the lesion beginning on the common iliac artery (5%) or extending to the femoral artery. In addition, the quadricipital artery and the profunda femoris artery can be affected, modifying the haemodynamic conclusions of the complementary examinations (8). At the beginning of our experience, there seemed to be a predilection for the left side, which is, however, affected in 52% of the cases we have treated to date. The problem is unilateral in 88.3% of our patients.

Etiopathogenesis

Several etiopathogenic factors, in all likelihood complementary, can explain the appearance and the development of this arterial lesion.

Anatomical factors

At the beginning of our experience, we noted that nearly 64% of patients presented one, two or even three

arteries of the psoas muscle. These collaterals anchor the EIA to the psoas muscle. The mobile portion of the EIA is thus shortened. In particular, it was noted in these athletes that the excess length of the artery was substantial, increasing the kinking phenomenon during pedalling movements.

The mobile iliac segment can extend to the termination of the common iliac artery in cases of a high division of the abdominal aorta (L2-L3 vertebrae). The kinking phenomenon extends proximally and contributes to the appearance of artery wall lesions on the common iliac artery. SCAVEE *et al.* emphasized that the EIA could be folded back and compressed by psoas muscle hypertrophy during pedalling movements (10).

Mechanical factors

The middle part of the EIA deforms physiologically during flexion-extension movements of the hip. When these movements are repeated with great amplitude, as in pedalling movements, the mobile portion of the artery progressively follows bends in the vessel that can lead to kinks. This so-called shroud-line theory explains the frequent existence of an excessive length of the EIA.

In parallel, the athlete produces a high level of constant effort during an extended period. Blood flow and shear force of arterial flow are thus at their maximum level in the lower extremities. This situation will induce stress lesions in the arterial wall, in particular in the arteries' large curves. This phenomenon is itself accentuated when the artery kinks temporarily, leading to artery wall trauma from the artery's burst of blood. The intima wall responds to this haemodynamic aggression

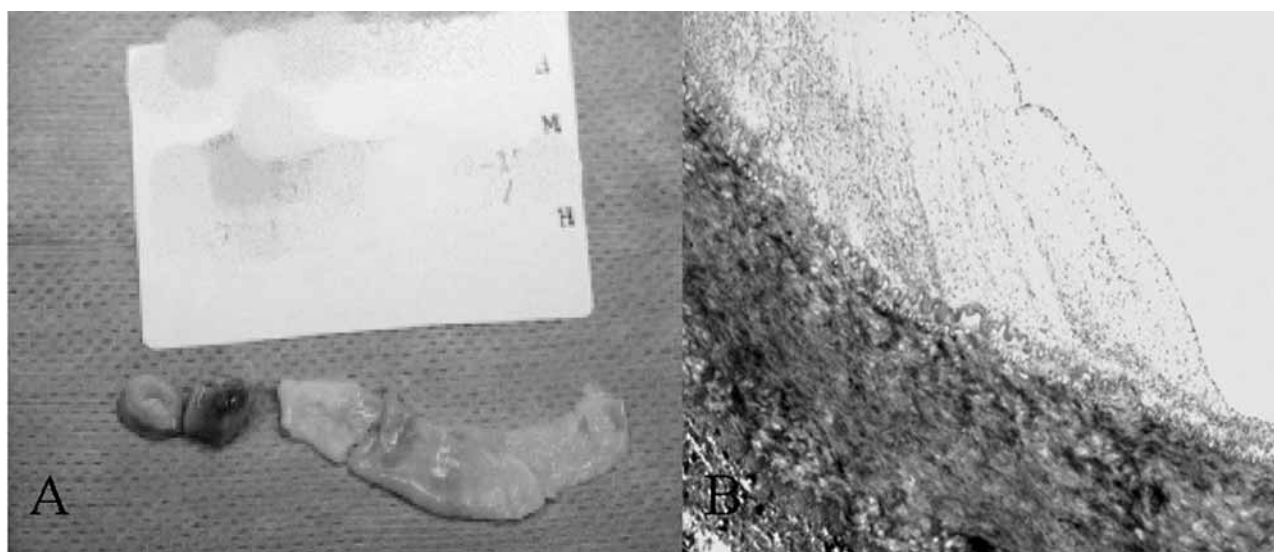


Fig. 1

External iliac endofibrosis : histological aspect

Pieces of arterial resection and plaque from endofibrosis after endofibrosectomy (A). Cross-section of an eccentric iliac endofibrosis lesion (colouration, haematein-phloxine-saffron ; magnification, 85 \times). The characteristic subendothelial intimal thickening made up of myofibroblasts and collagen can be seen (B).

by synthesizing reactional tissue similar to myo-intimal hyperplasia.

Hereditary and metabolic factors

Although several physiopathological theories have been postulated, they do not explain why the vast majority of cyclists present no arterial anomalies, nor why there are atypical arterial locations in this disease. Since 1995, we have been giving systematic doses of sulphur amino acids, in the search for a metabolism disorder. Nearly 75% of patients who have been operated on presented a significant increase in homocystinemia and homocystinuria after load exercise with methionine. These data suggest a metabolic predisposition as a minor dysfunction of the methionine cycle. This anomaly could explain why certain athletes may have an arterial predisposition which could be the subject of preventive medical treatment.

We have managed two brothers, both amateur cyclists, who declared a typical endofibrosis lesion a few years apart. They both had a minor amino acid metabolism disorder.

Clinical aspects of the disease

Functional signs

Careful questioning immediately orients suspicion toward arterial problems, because the pain is related to exercise and limits the athlete's performance to a certain threshold.

Ninety-four percent of our patients presented claudication of a lower limb at supramaximal exercise. Pain is described as a muscle contraction of the anterior aspect of the thigh or the impression of cycling shorts that are too tight, with onset during sprinting or hill climbing exertion. The association of both symptoms is found in 25% of those who consult. The pain can irradiate toward the buttocks or the leg. Very quickly, the limb feels paralysed and forces the patient to reduce or stop exercise.

Twelve patients (3.4%) presented an episode of subacute ischaemia of a lower limb that resolved spontaneously. The symptom appeared most often during the last moments of a race or a workout. It corresponded to thrombosis of the EIA, undoubtedly set off by the physical effort and a certain degree of dehydration. Because of the collateral aspect of the internal iliac, the clinical signs disappear. Intermittent claudication persists when walking, which should raise the question of iliac endofibrosis combined with thrombosis in the young athlete (16 patients, 4.6%).

Clinical signs

In most cases, clinical examination is normal. Other than rare cases of thrombotic complications, all pulses are apparent and there is no vascular murmur. Clinical examination generally does not confirm the diagnosis. A complementary workup is necessary.

Differential diagnoses

The diagnosis of iliac endofibrosis is sometimes discussed, either because of atypical clinical findings or discordant symptoms and exercise test results. Absence of pain in the thigh indicates another diagnosis. The sensation of a swollen thigh most often evokes a venous problem or compartment syndrome of the thigh. It is important to eliminate muscular pathology, a problem with the rectus femoris muscle tendon or an osteo-articular disorder of the hip or lumbar vertebrae. Atherosclerosis, iliac kinking, or fibromuscular dysplasia can produce the same symptoms (11).

Diagnostics tools

Echo-Doppler examination

Doppler exploration of the arteries of the lower limbs is always normal when at rest, with the exception of arterial thromboses. Several echographic anomalies have been recognized as signs of an endofibrosis lesion (12, 13). In nearly 60% of cases, thickening of the artery wall is found, only slightly echogenic, associated with an aspect of rigidity and moderate shrinkage of the arterial lumen. A finding of artery kinking is a positive element in the diagnosis (14). However, a normal echo-Doppler result should not eliminate the diagnosis.

The exercise test or the Strandness test

The Strandness test is the most important clinical test that can give a positive diagnosis for a problem to the EIA. It is done on a home trainer in conditions close to those that have brought on the pain. After exercise and the onset of pain, the presence of a drop in ankle blood pressure measurements from the 1st minute reveals asymptomatic arterial shrinkage at rest (15, 16). With a specificity and sensitivity in detecting moderate arterial lesions of 90% and 87% respectively, the ankle/humeral pressure index is the most informative (17). It is considered pathological when it is under 0.5 and suspect when there is no pain for values between 0.5 and 0.7 (18). However, absence of pressure variation does not eliminate an artery lesion located on the profunda femoris or the quadricipital artery.

The data from all patients examined with the exercise test are reported in Table 2.

Arteriography

Arteriography remains the reference examination and is requested in cases of a positive or suspect exercise test in a clinically suggestive context. The examination is done via a contralateral femoral bypass, following a standardized procedure to locate the often discrete stenosis, and quantifies the excessive length of the artery. Typically, a long stenosis (20-30%) is found,

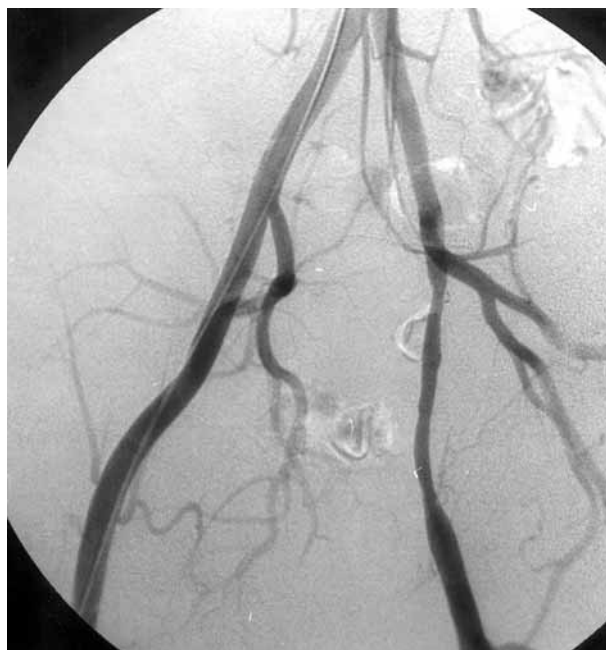

Fig. 2

Iliac endofibrosis

Characteristic arteriographic image in a severe case of left external iliac endofibrosis.

beginning at the origin of the EIA, revealing a rigidity in the artery wall in several incidences (Fig. 2). In case of more pronounced iliac artery thrombosis or stenosis warranting arterial bypass, the calibre of the internal iliac artery and the replacement of the artery and its collateral branches should be evaluated.

CT angiography and MRI angiography

Despite an improvement in the definition of artery reconstruction with new-generation devices, CT angiography and MRI angiography do not seem to improve the sensitivity of arteriography for stenoses that remain so difficult to detect. In addition, it remains difficult to evaluate the excess length of the artery and the deep arterial network with these devices.

Angioscopy

We have no experience with endoluminal ultrasound and its contribution to this problem. However, we systematically use angioscopy in two indications : 1) in patients requiring iliac revascularization surgery, to precisely locate the seat and extent of endofibrosis plaque and 2) when clinical examination and exercise tests arouse suspicion and arteriographic images provide little information.

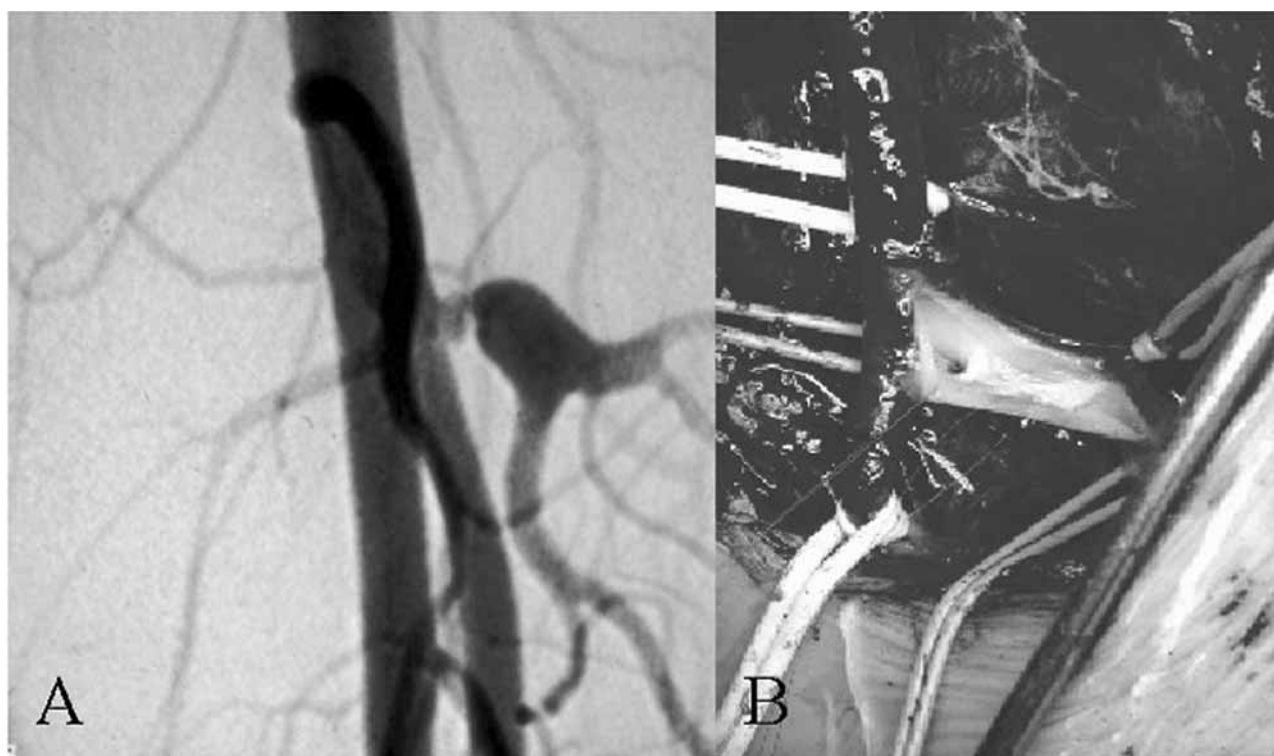


Fig. 3

Atypical location of arterial endofibrosis

Arteriographic image of the left femoral branching, confirming severe stenosis at the origin of the quadricipital artery that was responsible for typical clinical manifestations of pain at supramaximal exercise with a negative exercise test (A). Intra-operative view of re-implantation of the quadricipital artery (B).

Treatment options

Medical therapy

Although plaque progression seems to be stopped by stopping sports activity, the lesion does not disappear. However, since it is too discrete, it generally does not lead to any clinical consequence in daily life. Preventive anticoagulant or anti-platelet treatments are not justified. Currently, a pre- and postoperative preventive treatment of nutritional supplements and vitamins B1, B6 and folates is systematically given when minor hyperhomocysteinemia is detected.

Surgical Treatment

Percutaneous transluminal angioplasty

Endoluminal treatment with angioplasty appears to be a simple and ideal therapeutic solution for treating uncomplicated iliac endofibrosis. Although several authors have already reported a few isolated cases, we do not share enthusiasm for this therapeutic alternative (19, 20). Indeed, doubts can be raised on the efficacy of isolated angioplasty which can be for the treatment of an arterial wall lesion, which is by definition elastic and

soft. Immediate restenosis is inevitable and then requires the implantation of a stent. Moreover, angioplasty does not treat the excessive length of the artery, which is one of the possible etiopathogenic factors. Even in the case of perfect morphological control at the end of the endovascular procedure, the future outcome of a stent placed in the centre of the mobile arterial zone, in a young patient who wishes to continue training, is uncertain and should provoke debate. Although we have had to treat four patients with a compromised stent (restenosis due to myo-intimal hyperplasia, thrombosis due to kinking), we have also had to treat three cases of postangioplasty dissection, as have DEL GALLO *et al.* (6). We believe that endovascular treatment should be limited to isolated angioplasty for the rare professionals who must finish their racing season (21).

Revascularization surgery (3)

Treatment of endofibrosis is therefore first and foremost surgical. It is based on two techniques. The first, described as conservative, associates endofibrosectomy with the treatment of excessive length by shortening the artery and with closing the longitudinal arteriotomy by

Table 3
Results of our experience

Immediate results
– Morbidity : 2.57% (9 patients)
– Mean delay before returning to sport : 2.84 months (range, 2-6 months)
Long-term results
– Mean follow-up : 53 months
– Primary permeability : 90% at 5 years
– Secondary permeability : 100% at 5 years
– Return to sport : 332 patients (99%)
– Persistence of pain on exercise : 5 patients (1.5%)

venous or arterial closing angioplasty. The second responds to revascularization by saphenous bypass surgery, calibrated to the diameter of the affected iliac artery. Using a prosthetic patch or a vascular prosthesis should be proscribed, given that it creates a zone of rigidity, which is considered a factor of recurrence and thrombosis.

This indication is retained in patients who are motivated to return to competition. It is based on the patient's age (± 30 years), the length (± 5 cm), the homogenous and circumferential aspect of the lesion and on the possible recurrence of a lesion (22). Endofibrosectomy is the most frequently used operative technique. A venous graft should be used for all complicated lesions. These two techniques guarantee a rapid return to sports activity, with primary and secondary permeability greater than 90% and equal to 100% respectively, at 5 years (Table 3). In the great majority of cases, patients will be able to pursue their sports performance for several years.

References

1. WALDER J., MOSIMANN F., VAN MELLE G., MOSIMANN R. Iliac endofibrosis in 2 cycling racers. *Helv Chir Acta*, 1985, **51** (6) : 793-5.
2. CHEVALIER J. M., ENON B., WALDER J., BARRAL X., PILLET J., MEGRET A. *et al.* Endofibrosis of the external iliac artery in cycling racers : an unrecognized pathological state. *Ann Vasc Surg*, 1986, **1** (3) : 297-303.
3. CHEVALIER J., LOIRE R. Pathologie vasculaire du cycliste. In : *Encycl Méd Chir*. Paris : Elsevier, 1997, p. 11-675-A-10, 8 p.
4. PARAF F., PETIT B., ROUX J., BERTIN F., LASKAR M., LABROUSSE F. External iliac artery endofibrosis of the cyclist. *Ann Pathol*, 2000, **20** (3) : 232-4.
5. ROUSSELET M. C., SAINT ANDRÉ J. P., L'HOSTE P. H., ENON B., MEGRET A., CHEVALIER J. M. Stenotic intimal thickening of the external iliac artery in competition cyclists. *Hum Pathol*, 1990, **21** : 524-529.
6. DEL GALLO G., PLISSONNIER D., PLANET M., PEILLON C., TESTART J., WATELET J. [Dissecting aneurysm of the external iliac artery. An unusual course of endofibrosis in an athlete]. *J Mal Vasc*, 1996, **21** (2) : 95-7.
7. BRAY M. E., LEWIS W. A. Intermittent claudication in a professional rugby player. *J Vasc Surg*, 1992, **15** : 664-668.
8. CHEVALIER J. M., L'HOSTE P. H., BOUVAT E., MEGRET A., SAINT ANDRÉ J. P., RUVAULT P. H. L'endofibrose artérielle du sportif de haut niveau : formes inhabituelles. *J Traumatol Sport*, 1991, **8** : 176-181.
9. MASMOUDI S., FRIKHA I., HADJACEM A., YANGUI M., MNIF J., ELLEUCH H. *et al.* [Clinical case of the month. Iliac artery endofibrosis in a soccer player]. *Rev Med Liege*, 2002, **57** (3) : 135-7.
10. SCAVEE V., STAINIER L., DELTOMBE T., THEYS S., DELOS M., TRIGAUX J. P. *et al.* External iliac artery endofibrosis : a new possible predisposing factor. *J Vasc Surg*, 2003, **38** (1) : 180-2.
11. PILLET J., ENON B., REIGNE B., L'HOSTE P. Plication of the common femoral artery, a differential diagnosis with endofibrosis of the external iliac artery in racing cyclists. *J Chir (Paris)*, 1992, **129** (11) : 512-3.
12. ABRAHAM P., LEFTHERIOTIS G., BOURRE Y., CHEVALIER J. M., SAUMET J. L. Echography of external iliac artery endofibrosis in cyclists. *Am J Sports Med*, 1993, **21** (6) : 861-3.
13. ABRAHAM P., CHEVALIER J. M., LEFTHERIOTIS G., SAUMET J. L. Lower extremity arterial disease in sports. *Am J Sports Med*, 1997, **25** (4) : 581-4.
14. SCHEP G., BENDER M. H., SCHMIKLI S. L., WIJN P. F. Colour Doppler used to detect kinking and intravascular lesions in the iliac arteries in endurance athletes with claudication. *Eur J Ultrasound*, 2001, **14** (2-3) : 129-40.
15. FERNANDEZ-GARCIA B., ALVAREZ FERNANDEZ J., VEGA GARCIA F., TERRADOS N., RODRIGUEZ-ALONSO M., ALVAREZ RODRIGUEZ E. *et al.* Diagnosing external iliac endofibrosis by postexercise ankle to arm index in cyclists. *Med Sci Sports Exerc*, 2002, **34** (2) : 222-7.
16. TAYLOR A. J., GEORGE K. P. Ankle to brachial pressure index in normal subjects and trained cyclists with exercise-induced leg pain. *Med Sci Sports Exerc*, 2001, **33** (11) : 1862-7.
17. ABRAHAM P., BICKERT S., VIELLE B., CHEVALIER J. M., SAUMET J. L. Pressure measurements at rest and after heavy exercise to detect moderate arterial lesions in athletes. *J Vasc Surg*, 2001, **33** (4) : 721-7.
18. ABRAHAM P., SAUMET J. L., CHEVALIER J. M. External iliac artery endofibrosis in athletes. *Sports Med*, 1997, **24** (4) : 221-6.
19. FORD S. J., REHMAN A., BRADBURY A. W. External iliac endofibrosis in endurance athletes : a novel case in an endurance runner and a review of the literature. *Eur J Vasc Endovasc Surg*, 2003, **26** (6) : 629-34.
20. LEFEBVRE P., DUBOIS P., BRUNINX G., DELCOUR C., WAUTRECHT J. C. Intermittent claudication in a young patient. A case of isolated fibromuscular dysplasia of the external iliac artery. *Ann Cardiol Angeiol (Paris)*, 1999, **48** (1) : 7-9.
21. WIJESINGHE L. D., COUGHLIN P. A., ROBERTSON I., KESSEL D., KENT P. J., KESTER R. C. Cyclist's iliac syndrome : temporary relief by balloon angioplasty. *Br J Sports Med*, 2001, **35** (1) : 70-1.
22. ABRAHAM P., CHEVALIER J. M., SAUMET J. L. External iliac artery endofibrosis : a 40-year course. *J Sports Med Phys Fitness*, 1997, **37** (4) : 297-300.

Dr. P. Feugier
Service de Chirurgie Vasculaire, Hôpital E Herriot
Place d'Arsonval – 69 437 Lyon Cedex 03
Tel. : 00 33 472 11 78 07
Fax : 00 33 472 11 75 57
E-mail : patrickfeugier@hotmail.com